


PATIENT PRESENTING CLINICAL SIGNS

PATIENT Arlo Galligan History: 4-week duration of hyporexia and weight loss, diarrhea past 5 days which become hemorrhagic 2 days ago.

SPECIES Canine Physical Examination: N/A.

BREED Pit Bull terrier Mix Urinalysis: N/A.

SEX Intact Male CBC: N/A.

AGE 2 years Serum Biochemistry: N/A.

WEIGHT 59 # Radiographic Findings: N/A.

INTERPRETED BY

Remo Lobetti, BVSc,
MMedVet (Med), PhD,
Dipl. ECVIM

IMAGING PERFORMED BY

Sonya Myers, DVM

HOSPITAL NAME

Oviedo Veterinary Care
and Emergency

REFERRING VET

Dr Caja

INVOICE

303041

DATE

6/17/22

ULTRASONOGRAPHIC EXAMINATION OF THE ABDOMEN
Urinary System

Full urinary bladder with a normal thickness and appearance of the wall. Normal anechoic urine with no sediment or uroliths evident.

Normal trigone area, proximal urethra (0.7 cm), and iliac blood vessels.

Enlarged iliac lymph nodes (1.1 x 2.7 cm, 1.6 x 3.5 cm) with a rounded and increased echogenic appearance. Ureters not visualized.

Renomegaly (left 7.3 cm, right 7.8 cm) with increased echogenic appearance, some loss of cortico-medullary differentiation, and normal pelvis, and capsule.

Reproductive System

Normal size and echogenic appearance of the prostate (3 cm). Normal appearance of the testes.

Adrenal Glands

Normal shape, echogenic appearance, size, and position. Left 0.66/0.69 cm, right 0.72/0.72 cm.

Spleen

Normal size (2.7 cm) with an increased and nodular echogenic appearance. Smooth homogenous parenchyma, smooth curvi-linear capsule, and normal vasculature. Nodules are small, faint hypoechoic and parenchymal.

Liver

Enlarged with rounded edges, mottled hyperechogenic appearance, and hyperechogenic portal markings. No nodules or masses evident. Full gall bladder containing small amount of adherent hyperechogenic sediment. Thickened and hyperechogenic appearance of the gall bladder wall. Normal bile duct (0.2 cm).

**PATIENT*****Gastrointestinal***

Arlo Galligan

Diffuse thickening of the stomach (0.58 cm), duodenum (0.94 cm), small intestine (0.7 cm), and colon (0.8 cm) with no loss of layering, normal peristaltic activity and no distension of the lumen. Focal hypoechoic mass in the gastric wall (2.1 x 2.6 cm).

SPECIES

Canine

Pancreas**BREED**

Pit Bull terrier Mix

Normal size and echogenic appearance. Normal echogenic appearance of the mesentery and fat surrounding the pancreas.

SEX

Intact Male

Free Abdomen

Mesenteric lymphadenomegaly (4.7 x 7.8 cm) with a rounded and hyperechogenic appearance. FNA taken with no obvious post aspirate hemorrhage. Small amount of ascites.

AGE

2 years

ULTRASONOGRAPHIC FINDINGS

Primary Findings:

- Renomegaly.
- Splenic pathology.
- Mesenteric and iliac lymphadenomegaly.
- Hepatopathy.
- Gastroenteropathy.
- Gastric nodule.

WEIGHT

59 #

Secondary Findings:

- Previous cholecystitis.

INTERPRETED BY

Remo Lobetti, BVSc,
MMedVet (Med), PhD,
Dipl. ECVIM

IMAGING PERFORMED BY

Sonya Myers, DVM

HOSPITAL NAME

Oviedo Veterinary Care
and Emergency

REFERRING VET

Dr Caja

INTERPRETATION OF THE FINDINGS & FURTHER RECOMMENDATIONS

With these ultrasound findings the most likely diagnosis would be lymphoma with granulomatous disease a differential diagnosis. The appearance of the pancreas is consistent with pancreatitis with fibrosis, a differential diagnosis.

Further assessment/therapy needs to be based on the results of the FNA aspirate

INVOICE

303041

DATE

6/17/22



PATIENT

Arlo Galligan

SPECIES

Canine

BREED

Pit Bull terrier Mix

SEX

Intact Male

AGE

2 years

WEIGHT

59 #

INTERPRETED BY

Remo Lobetti, BVSc,
 MMedVet (Med), PhD,
 Dipl. ECVIM

IMAGING PERFORMED BY

Sonya Myers, DVM

HOSPITAL NAME

Oviedo Veterinary Care
 and Emergency

REFERRING VET

Dr Caja

INVOICE

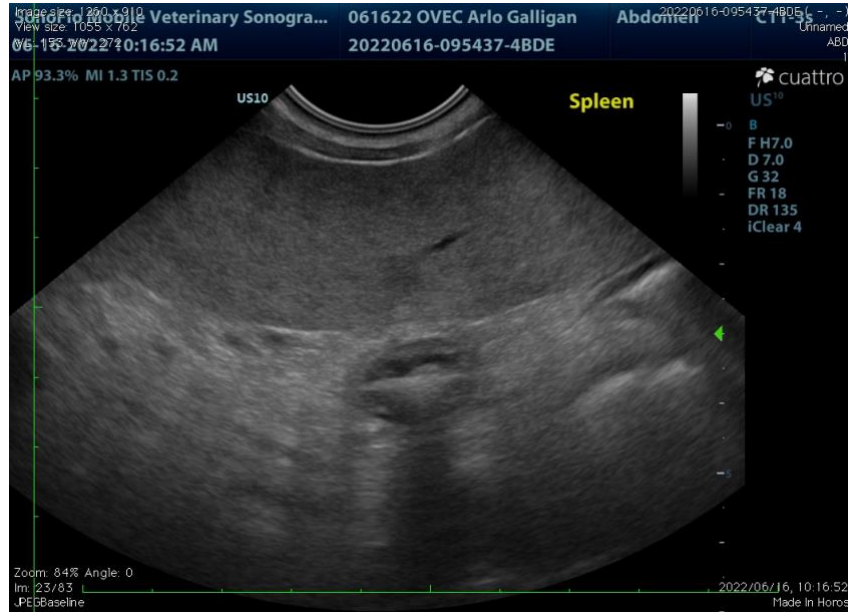303041

DATE

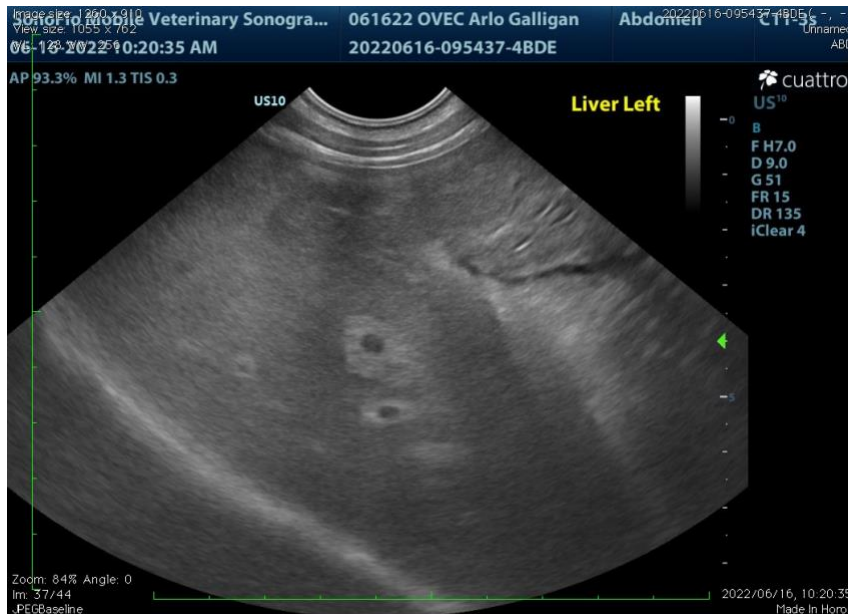6/17/22

IMAGES

Spleen



Liver





PATIENT Stomach

Arlo Galligan

SPECIES

Canine

BREED

Pit Bull terrier Mix

SEX

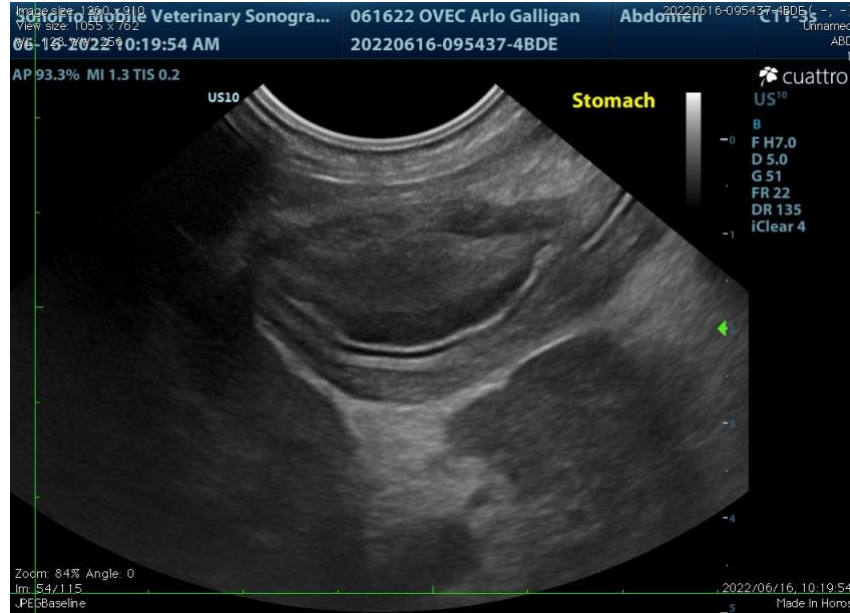
Intact Male

AGE

2 years

WEIGHT

59 #



Colon

INTERPRETED BY

Remo Lobetti, BVSc,
 MMedVet (Med), PhD,
 Dipl. ECVIM

IMAGING PERFORMED BY

Sonya Myers, DVM

HOSPITAL NAME

Oviedo Veterinary Care
 and Emergency

REFERRING VET

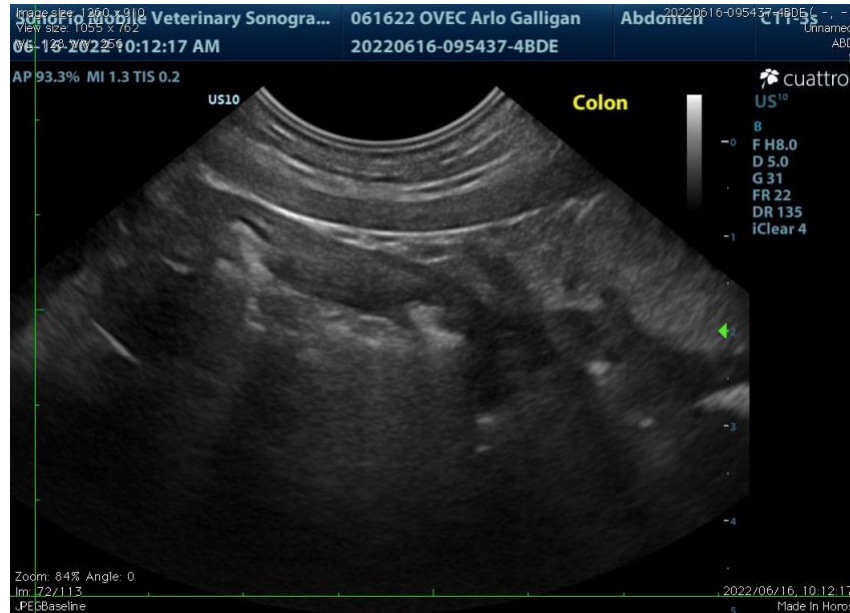Dr Caja

INVOICE

303041

DATE

6/17/22





PATIENT

Mesenteric lymph node

Arlo Galligan

SPECIES

Canine

BREED

Pit Bull terrier Mix

SEX

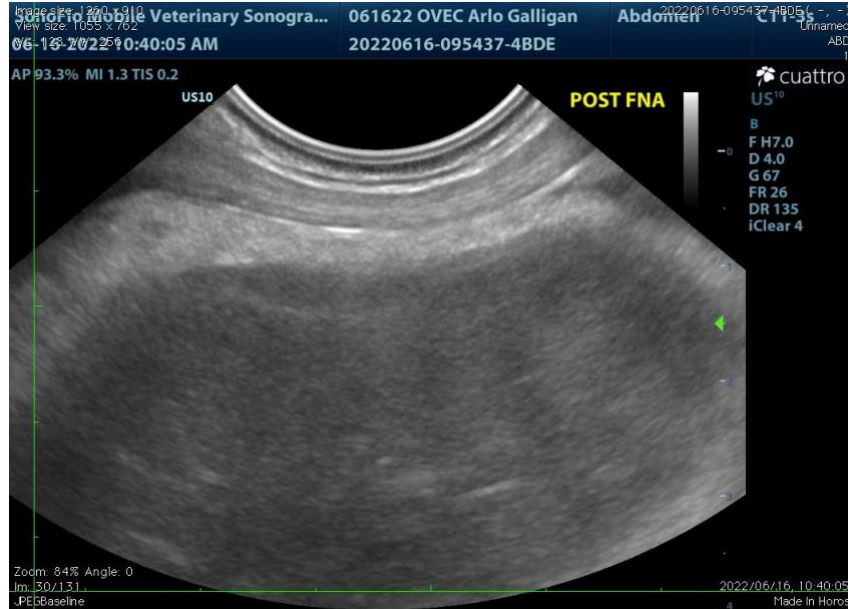Intact Male

AGE

2 years

WEIGHT

59 #



INTERPRETED BY

Remo Lobetti, BVSc,
 MMedVet (Med), PhD,
 Dipl. ECVIM

The information and recommendations provided are based on the images presented by the referring veterinarian. No evaluation can be communicated regarding pathology that was not visible in the image/video clips provided.

Thank you for this referral. If the clinical or image interpretation does not parallel your findings or if I can be of any further assistance, please contact me.

IMAGING PERFORMED BY

Sonya Myers, DVM

Remo Lobetti, BVSc, MMedVet (Med), PhD, Dipl. ECVIM (Internal Medicine)
rlobetti@mweb.co.za

HOSPITAL NAME

Oviedo Veterinary Care
 and Emergency

REFERRING VET

Dr Caja

INVOICE

303041

DATE

6/17/22